

Meniscus Subluxation Retensioning: “Autotransplant”



João Espregueira-Mendes, M.D., Ph.D., Renato Andrade, B.Sc., Luís Silva, M.D.,
Bruno Pereira, M.D., Nuno Sevivas, M.D., Ph.D., and Ricardo Bastos, M.D., Ph.D.

Abstract: Knee osteoarthritis (OA) is a common condition in the older population and is characterized by several articular dysfunctions with consequent anatomic abnormalities including osteochondral degenerative changes and meniscal extrusion. Meniscal damage with extrusion is one of the strongest identified risk factors for the development and progression of knee OA and represents an important factor in the long-term health of the joint. Meniscal extrusion can alter normal knee biomechanics and dramatically inhibit meniscal function. We present a surgical technique for the treatment of early knee OA in association with an extruded meniscus to restore the meniscal anatomic position and preserve its native physiological function related to cartilage preservation. Meniscal retensioning, or a “meniscal autotransplant,” can increase meniscal coverage in the compromised compartment, prevent cartilage degeneration, decrease subchondral bone exposure, and restore the compartmental space and, consequently, can relieve patients’ symptoms related to early OA.

Knee osteoarthritis (OA) is a common condition in the older population. Nowadays, it represents one of the leading causes of disability in the world, with a high associated socioeconomic impact.¹ The disease is characterized by several articular dysfunctions with consequent anatomic abnormalities including osteochondral degenerative changes and meniscal extrusion.

The meniscus is an integral part of the complex biomechanical system of the knee, which is crucial in distributing and absorbing the force load by increasing the contact surface area and providing uniform distribution of weight bearing across the articular surfaces.

Damage to the meniscus modifies the pattern of load distribution and contributes to compartmental instability. Meniscal damage is one of the strongest identified risk factors for the development and progression of knee OA and represents an important factor in the long-term health of the joint.^{2,3} Meniscal injury can lead to the development of knee OA, but osteoarthritic knees can also result in a spontaneous meniscal tear and extrusion through breakdown and weakening of meniscal structure.⁴ Meniscal extrusion is considered when the peripheral meniscus extends beyond the tibial margin. This abnormality can alter

From the Orthopaedics Department of Minho University (J.E-M.), Braga, Portugal; Clínica do Dragão, Espregueira-Mendes Sports Centre—FIFA Medical Centre of Excellence (J.E-M., R.A., L.S., B.P., N.S., R.B.), Porto, Portugal; Dom Henrique Research Centre (J.E-M., R.A., L.S., B.P., N.S., R.B.), Porto, Portugal; 3B’s Research Group—Biomaterials, Biodegradables and Biomimetics, University of Minho, Headquarters of the European Institute of Excellence on Tissue Engineering and Regenerative Medicine, AvePark, Parque de Ciência e Tecnologia, Zona Industrial da Gandra (J.E-M.), Barco, Portugal; ICVS/3B’s—PT Government Associate Laboratory (J.E-M., N.S.), Braga-Guimarães, Portugal; Faculty of Sports, University of Porto (R.A.), Porto, Portugal; Hôpital Riviera-Chablais (L.S.), Vaud-Valais, Switzerland; Orthopaedics Department, Hospital de Braga (B.P., N.S.), Braga, Portugal; Life and Health Sciences Research Institute (ICVS), School of Medicine, University of Minho, Campus de Gualtar (N.S.), Braga, Portugal; and Fluminense Federal University (R.B.), Niterói, Brazil.

The authors report the following potential conflicts of interest or sources of funding: The experimental work (arthroscopy laboratory) and surgical

equipment were financially supported by Arthrex. Video 1 was edited by Arthrex. J.E-M. received support for travel-related expenses and laboratory equipment from Arthrex for this study. R.B. received support for travel-related expenses and laboratory equipment from Arthrex for this study. Full ICMJE author disclosure forms are available for this article online, as [supplementary material](#).

Received October 17, 2018; accepted November 6, 2018.

Address correspondence to João Espregueira-Mendes, M.D., Ph.D., Clínica do Dragão, Espregueira-Mendes Sports Centre - FIFA Medical Centre of Excellence - F. C. Porto Stadium, Entrada Nascente, Piso -3, 4350-415 Porto, Portugal. E-mail: espregueira@dhresearchcentre.com

© 2018 by the Arthroscopy Association of North America. Published by Elsevier. This is an open access article under the CC BY-NC-ND license (<http://creativecommons.org/licenses/by-nc-nd/4.0/>).

2212-6287/181266

<https://doi.org/10.1016/j.eats.2018.11.007>

Table 1. Key Points of Surgical Procedure

The patient is positioned supine with the tourniquet at the proximal thigh.

Parapatellar anteromedial and anterolateral arthroscopic portals are used.

The distance between the anterior and posterior attachments of the meniscus is measured, and the landmarks for the anterior and posterior tibial tunnels (10 mm anteriorly to the posterior insertion and 10 mm posteriorly to the anterior insertion, respectively) are identified.

Two 6-mm tunnels are drilled with an Arthrex Meniscal Root Marking Hook and a 6-mm Arthrex FlipCutter is performed (1) through the anterolateral cortex of the tibia to 10 mm anteriorly to the posterior attachment of the meniscus and (2) through the anteromedial cortex of the tibia to 10 mm posteriorly to the anterior attachment of the meniscus.

Two fixation points are used for the posterior horn of the meniscus. By use of two 1.3-mm SutureTapes, (1) the first stitch is situated 20 mm medially to the posterior insertion of the meniscus and (2) the second stitch is made 10 mm medially to the first stitch.

One fixation point is used for the anterior horn of the meniscus with a 1.3-mm SutureTape.

Passage of the SutureTapes is performed through the respective tibial tunnels. Tensioning is applied to the tapes until the mid portion and posterior horn of the meniscus displace to the original situation. Joint space opening can easily be noticed.

Tibial fixation is performed with two 11-mm Arthrex Concave ABS Buttons and a 4-mm collar after application of the final desired meniscal tension.

normal knee biomechanics and dramatically inhibit meniscal function. It results from the disruption of collagen fibers that provide hoop strength, leading to a condition comparable with a total meniscectomy that is directly related to progression of OA.⁵

Considering the strict relation between meniscal structure and cartilage tissue, procedures involving meniscal replacement have been proposed. Meniscal allograft transplantation has been performed in an attempt to improve symptoms and delay the

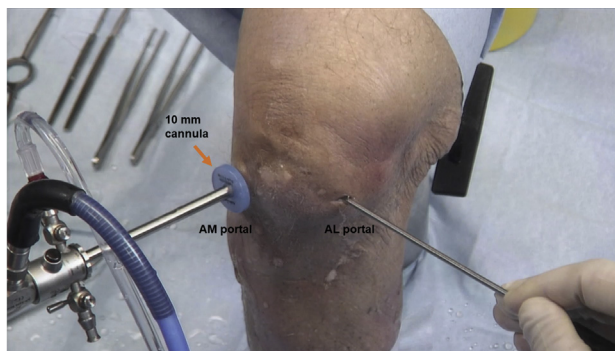


Fig 1. A left knee is shown with the patient supine; an anteromedial (AM) viewing portal is used. Conventional AM and anterolateral (AL) arthroscopic portals are established. A 10-mm cannula (Arthrex PassPort Button Cannula) is used in the AM portal to facilitate the procedure.

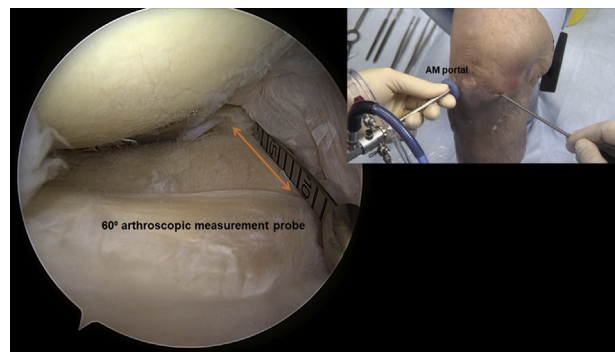


Fig 2. A left knee is shown with the patient supine; an anteromedial (AM) viewing portal is used. The exit points of the anterior and posterior guide pins and tibial tunnels (10 mm anteriorly to the posterior attachment and 10 mm posteriorly to the anterior attachment of the meniscus) are identified. The arrow shows the measurement of the distance between the anterior and posterior meniscal horns.

progression of joint degeneration in a meniscus-deficient compartment, with good results in the literature.^{6,7}

Nowadays, with an increased trend for sports practice, OA occurs at younger ages and persons are less amenable to change their lifestyles, stimulating the development of more effective approaches. Nonetheless, treatment is still insufficient for the requirements of such an active population. Nonsurgical treatment is often palliative. Surgical treatment shows consistent results but is more invasive and more prone to complications. In light of these observations, we present a surgical technique for the treatment of early knee OA in association with an extruded meniscus to restore the meniscal anatomic position and preserve its native physiological function related to cartilage preservation.

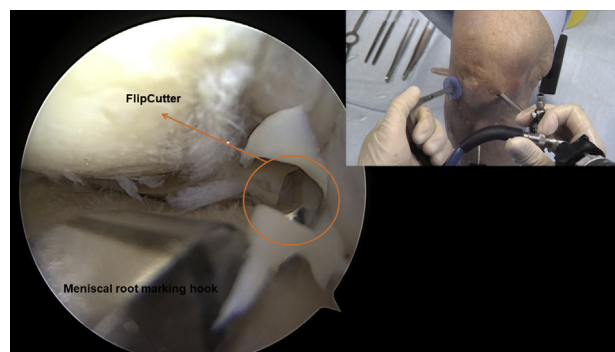


Fig 3. A left knee is shown with the patient supine; an anterolateral viewing portal is used. A 6-mm inside-out tunnel is drilled from 10 mm anteriorly to the posterior attachment of the meniscus to the anterolateral cortex of the tibia.

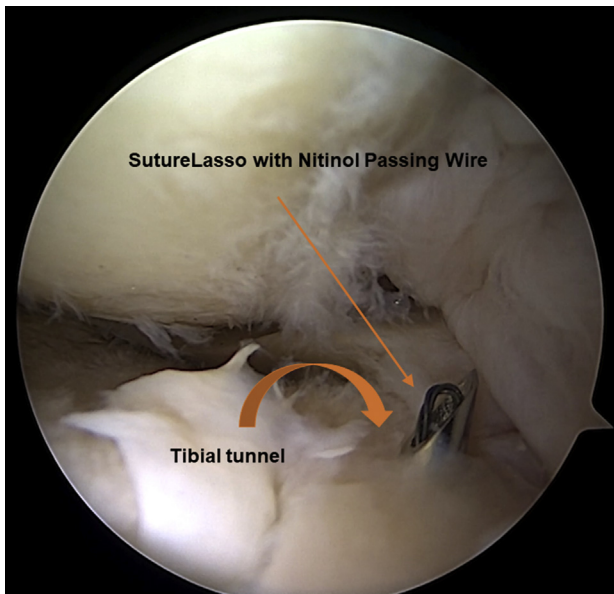


Fig 4. A left knee is shown with the patient supine; an anterolateral viewing portal is used. A SutureLasso with a nitinol passing wire is passed through the tibial tunnel.

Surgical Technique

Preoperative Planning and Patient Setup

The surgical decision is made after a careful clinical history is taken and physical examination performed. Knee pain is the main symptom and mostly focused in 1 compartment of the knee (medial or lateral). The knee must be stable in terms of ligament integrity. Patellofemoral pain must be absent or less important during the physical examination. A normal limb axis is desired. Associated varus or valgus malalignment should be corrected previously or concomitantly with the proposed meniscal procedure by a tibial or femoral osteotomy. Imaging evaluation of the knee joint (radiography and magnetic resonance imaging) and lower limb (long-axis radiography) is performed for confirmation of the diagnosis of unicompartmental knee OA (Kellgren-Lawrence grade 1-3) with meniscal extrusion situated in the damaged compartment and normal limb alignment.

The choice of anesthesia is made in conjunction with the patient, anesthesiologist, and surgeon, with the different factors influencing the preferred anesthesia technique being taken into account, such as the patient's comorbid medical problems. The patient is positioned supine with the tourniquet at the proximal thigh, and the limb is disinfected.

Surgical Approach

The described surgical technique is referred to as a "medial meniscus subluxation retensioning procedure" (Table 1, Video 1). The same technique, with exchanged

arthroscopic portals, can be used for the lateral meniscus. First, conventional anteromedial and anterolateral arthroscopic portals are created. A 10-mm cannula (Arthrex PassPort Button Cannula) is used in the medial portal to facilitate the procedure (Fig 1). An evaluation of all intra-articular compartments is made, and the distance between the anterior and posterior meniscal root insertions is measured with a 60° arthroscopic measurement probe, introduced through the anteromedial portal (Fig 2). This step is crucial to identify the precise location of the exit point of the anterior and posterior guide pins and the location of the tibial tunnels (10 mm anteriorly to the posterior attachment and 10 mm posteriorly to the anterior attachment of the meniscus). This can prevent meniscal root over-tensioning (increase of distance) or insufficient tensioning (tibial tunnel too close to meniscal attachment).

By use of a meniscal root marking hook (Arthrex), a 6-mm inside-out tunnel is drilled (Arthrex FlipCutter II) from 10 mm anteriorly to the posterior attachment of the meniscus to the anterolateral cortex of the tibia (Fig 3). A SutureLasso (Arthrex) with a nitinol passing wire is then passed through the tibial tunnel (Fig 4) and recovered with a mini-suture retriever (Arthrex) through the anteromedial portal (Fig 5). A loop is created with a No. 2-0 FiberWire (AR-7200; Arthrex) as a shuttle suture and is passed down through the tibial tunnel. The FiberWire loop is pulled out at the anteromedial portal while the 2 limbs of the suture pass through the tibia (Fig 6).

A Knee Scorpion Suture Passer (AR-12990; Arthrex) preloaded with a 1.3-mm SutureTape (AR-7500; Arthrex) is used to tie the mid portion of the posterior horn of the meniscus 20 mm medially to its insertion (Fig 7, Table 2). A superficial central suture can eventually predispose a meniscal tear to occur during tensioning (Table 2). Consequently, a second stitch is made 10 mm medially to the first tape with another

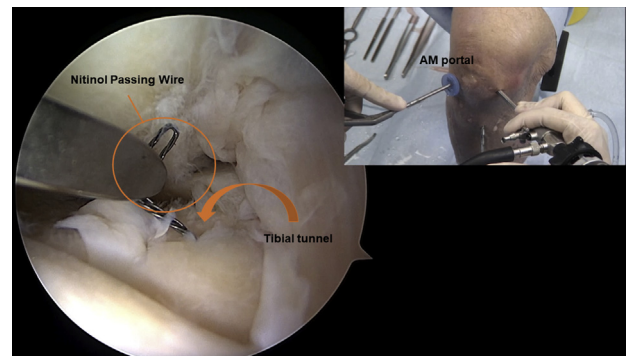


Fig 5. A left knee is shown with the patient supine; an anterolateral viewing portal is used. The nitinol passing wire is recovered with a suture retriever through the anteromedial (AM) portal.

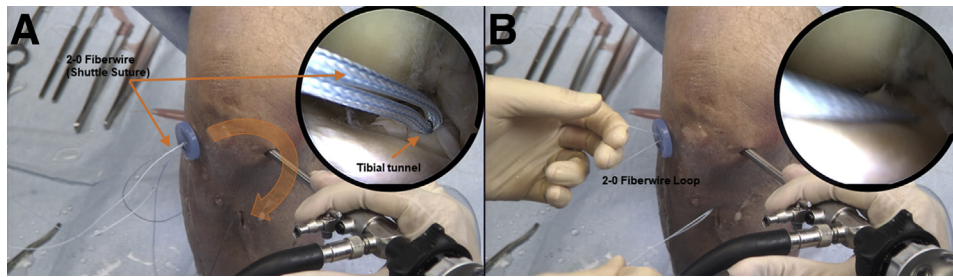


Fig 6. A left knee is shown with the patient supine; an anterolateral viewing portal is used. (A) The No. 2-0 FiberWire is passed down through the tibial tunnel. (B) The No. 2-0 FiberWire loop is created as a shuttle suture at the anteromedial portal. The curved arrow shows the passage of the No. 2-0 FiberWire from its entrance at the anteromedial portal to its exit at the anterolateral tibial cortex.

1.3-mm SutureTape. Both tapes are passed through the tibial tunnel using the FiberWire loop previously prepared (Fig 8). With application of tension to the tapes, anteriorization of the posterior horn of the meniscus is evaluated and articular space opening can be observed (Fig 9).

An anterior tunnel is created with the same technique as the posterior tunnel. The 6-mm tunnel is drilled from 10 mm posteriorly to the meniscal anterior horn attachment to the anteromedial cortex of the tibia (Fig 10). An Arthrex 45°, Curve, Right QuickPass Lasso (AR-6068-45R) is used to punch the mid portion of the anterior horn of the meniscal thickness 20 mm medially from the anterior attachment (Fig 11). A SutureTape is passed through the meniscus and tibial tunnel (Fig 12).

After suturing of the anterior and posterior meniscal horns, tensioning is applied to the tapes until the meniscus displaces to its original position, with the peripheral limits of the tibial joint surface being taken as a reference. It is important to place adequate tensioning. Over-tensioning can cause a meniscal tear and SutureTape rupture and, consequently, retensioning failure. Insufficient tension can result in undesirable results in restoring proposed meniscal protection. The mid portion of the extruded meniscus is reduced and centralized, and the joint space opening can easily be noticed. Tibial fixation is finally performed with two 11-mm Concave ABS Buttons (Arthrex) and two 4-mm collars (AR-1588TB-3; Arthrex) after the final desired tension is achieved (Fig 13).

Postoperative Rehabilitation

The patient is allowed to immediately start active flexion of the knee. However, during the first 4 weeks, flexion is limited to 90°. Partial weight bearing is maintained during the initial 6 weeks. After 6 weeks, range of motion is increased as tolerated and full weight bearing is gradually permitted. Rehabilitation is focused on restoring full knee range of motion, patellar

mobilization, preoperative quadriceps muscle activation and strength, effusion control, and pain management.

Discussion

The development of an effective treatment for knee OA remains a challenge for orthopaedic surgeons and researchers. Because of the particular biological characteristics observed in the cartilage tissue, the poor capacity for regeneration results in this disease being considered irreversible.⁸ Thus, all efforts have been focused on preventing the progression of cartilage degeneration. Meniscal repairs, knee ligament reconstructions, and osteotomies have the main objective of preventing the development of OA, with good results in the literature.^{9,10}

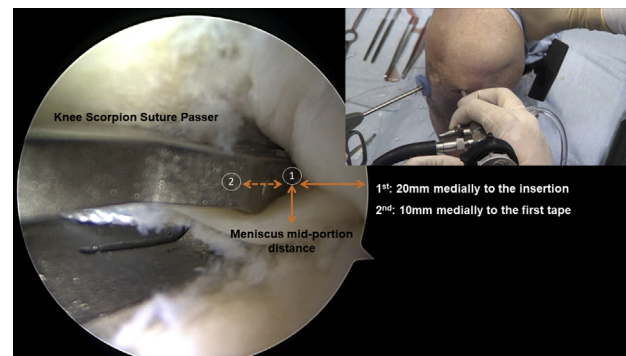


Fig 7. A left knee is shown with the patient supine; an anterolateral viewing portal is used. A Knee Scorpion Suture Passer preloaded with a 1.3-mm SutureTape is used to tie the mid portion of the posterior horn of the meniscus 20 mm medially to its insertion. Consequently, a second stitch is made 10 mm medially to the first tape with another 1.3-mm SutureTape. The arrows show the SutureTape fixation points at the posterior horn of the meniscus. (1) The first point is located on the mid portion of the posterior horn and 20 mm medially to the posterior meniscal attachment, and (2) the second point is 10 mm medially to the first point.

Table 2. Pearls and Pitfalls

Pearls	Pitfalls
The exit point related to the anterior and posterior tibial tunnels should be correctly identified.	An increased distance from the tibial tunnels to the anterior or posterior meniscal attachment can lead to over-tensioning. Over-tensioning can cause a meniscal tear and SutureTape rupture and, consequently, retensioning failure.
Meniscal fixation must be performed in the mid portion of the meniscal thickness.	Superficial central fixation with insufficient tissue can cause a meniscal lesion and loss of fixation.
A distance of 10 mm between the 2 stitches in the posterior horn of the meniscus must be respected.	An insufficient distance between sutures can cause a meniscal tear and communication of the 2 fixation points. An increased distance between the 2 points of fixation can overload the second stitch.
Appropriate tension has to be placed on both SutureTapes. Careful evaluation of meniscal displacement and joint space opening must be observed arthroscopically. The meniscus must be placed at its original position, with the peripheral limits of the tibial joint surface being taken as a reference.	Nonanatomic intra-articular placement of the meniscus can cause pain or a tear by over-tensioning.
Care should be taken in maintaining final tensioning during tibial fixation with a 11-mm button and a 4-mm collar. Tibial fixation must be performed with direct arthroscopic view control.	Loss of tension during tibial fixation can lead to insufficient results.

However, once degenerative findings are observed, an effective and lasting treatment is not available and, most often, total knee replacements are indicated to relieve pain and improve the patient's quality of life.

The meniscus has an important role in the prevention of cartilage degeneration. Radiographic changes observed in osteoarthritic knees after meniscal extrusion can be explained by compartmental space narrowing, thinning of the articular cartilage, and limb alignment changes (varus or valgus) after loss of meniscal function owing to extrusion.¹¹ Therefore, when meniscal extrusion occurs, restoration of the native meniscal position and function has the objective of re-establishing the protective function of the meniscus in terms of absorption and distribution of forces.

The literature shows strong evidence about the benefits of restoring the biomechanical properties of the meniscus. Meniscal root repair in cases of traumatic tears leading to extruded menisci has been described as a procedure that can effectively prevent OA.⁹ Moreover, meniscal transplantation has shown significant benefits in terms of decreasing pain and improving functional scores in cases of early OA in post-meniscectomy knees.¹² The presented surgical technique aims to provide a less invasive and biological treatment for uni-compartmental OA that can simultaneously assemble the purpose of a meniscal root repair and a meniscal transplantation. Through retensioning of the native extruded undamaged meniscus, we can observe a "meniscal autotransplant." This denomination seems

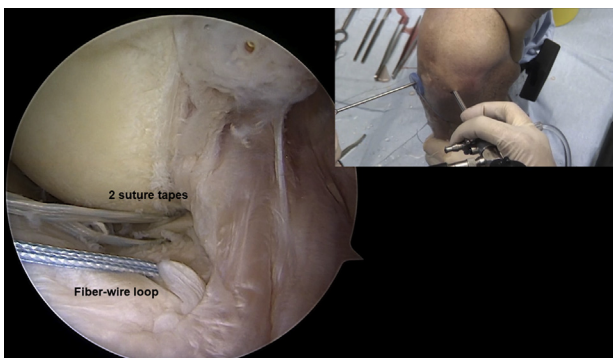


Fig 8. A left knee is shown with the patient supine; an anterolateral viewing portal is used. Both tapes are passed through the tibial tunnel using the FiberWire loop previously prepared.

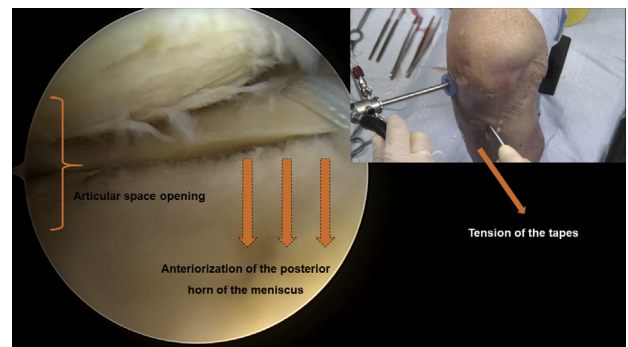


Fig 9. A left knee is shown with the patient supine; an anteromedial viewing portal is used. With application of tension to the tapes, anteriorization of the posterior horn of the meniscus is evaluated and articular space opening can be observed. The bracket symbol represents the joint space opening, and the vertical downward arrows show the anteriorization of the posterior horn of the extruded meniscus.

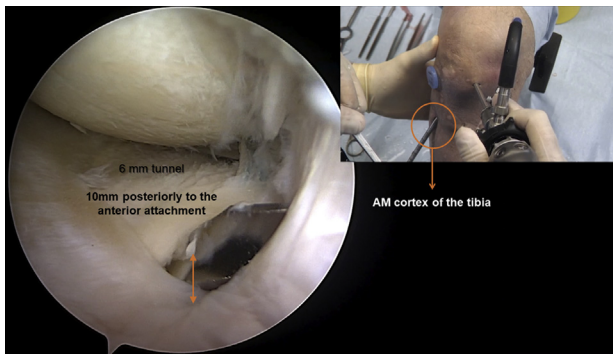


Fig 10. A left knee is shown with the patient supine; an anterolateral viewing portal is used. A 6-mm tunnel is drilled from 10 mm posteriorly to the meniscal anterior horn attachment to the anteromedial (AM) cortex of the tibia. The arrow shows the FlipCutter exit point, which is 10 mm posteriorly to the anterior attachment of the meniscus.

very appropriate because the protective function of the meniscus can be restored in a patient in whom meniscectomy is considered to have occurred biomechanically because of the extrusion. The presented arthroscopic procedure is a minimally invasive option for the treatment for early OA that can relieve pain symptoms, avoid disease progression, and postpone the need for more complex surgical procedures such as knee replacement (Table 3).

The procedure has the advantage of being easily performed simultaneously with microfracture, osteotomy, or ligament repair. Associated procedures can aggregate potential benefits of the treatment, adding multiple biomechanical and biological adjustments. Thus, correction of the

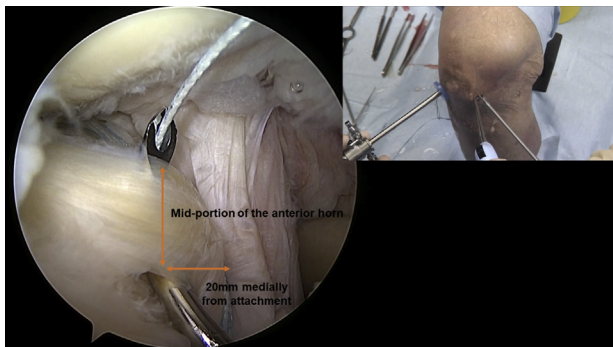


Fig 11. A left knee is shown with the patient supine; an anteromedial viewing portal is used. A 45°, Curve QuickPass Lasso is used to punch the mid portion of the anterior horn of the meniscal thickness 20 mm medially from the anterior attachment. The arrows show the SutureTape fixation point at the anterior horn of the meniscus. The point is located on the mid portion of the anterior horn and 20 mm medially to the anterior meniscal attachment.

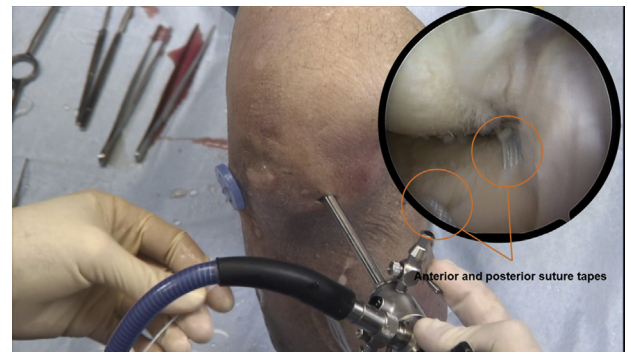


Fig 12. A left knee is shown with the patient supine; an anteromedial viewing portal is used. A SutureTape is passed through the meniscus and the anterior tibial tunnel.

mechanical axis (osteotomy), fibrocartilage growth stimulation (microfracture), restoration of knee stability (ligament reconstruction), and re-establishment of meniscal function (meniscal retensioning) can be associated in the same surgical procedure and correct different factors involved in the physiopathology of knee OA.

The potential benefits to restoring the native position and biomechanical function of the meniscus are limited to the cartilage degeneration severity. Meniscal retensioning for the treatment of severe OA (Kellgren-Lawrence grade 3 or 4) is contraindicated.

In summary, meniscal retensioning, or a meniscal autotransplant, can increase meniscal coverage in the compromised compartment, prevent cartilage degeneration, decrease subchondral bone exposure, and restore the compartmental space and, consequently, can relieve patients' symptoms related to early OA.

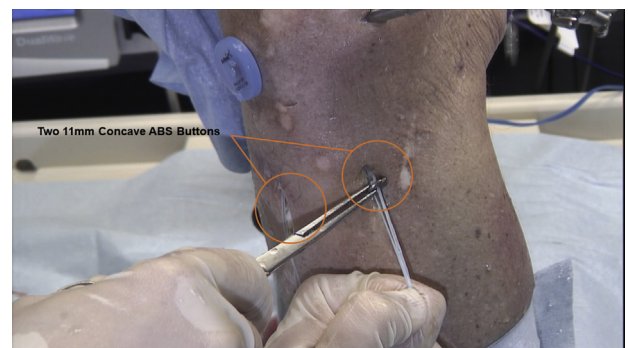


Fig 13. A left knee is shown with the patient supine. Tibial fixation is performed with two 11-mm Concave ABS Buttons after the final desired tension is achieved.

Table 3. Advantages, Risks, and Limitations of Presented Technique

Advantages	Risks and Limitations
The procedure can be considered a meniscal autotransplant procedure. Native meniscal biomechanical function can be restored in an extruded meniscus.	Over-tensioning of the meniscus may cause postoperative pain caused by nonanatomic placement and a meniscal tear. Under-tensioning of the meniscus may lead to failure of the results.
The procedure is a minimally invasive and biological treatment for early OA that can relieve pain symptoms and avoid disease progression, restoring the protective function of the meniscus.	Meniscal fixation can result in a meniscal tear and loss of tension.
The need for a total or partial knee replacement can be postponed.	The indications are restricted to early OA and meniscal extrusion with a stable knee and without previously corrected limb alignment deviation.
The procedure can be easily used concomitantly with other procedures (e.g., tibial or femoral realignment osteotomies, ligament reconstructions, or cartilage procedures).	Restoring cartilage degeneration is impossible.
The compartment joint space can be restored.	The technique is not indicated for the treatment of severe OA.
Meniscal coverage in the compromised compartment can be increased.	
Subchondral bone exposure can be decreased.	
Cartilage degeneration can be prevented.	
A short-term rehabilitation protocol is required.	

OA, osteoarthritis.

References

1. Cross M, Smith E, Hoy D, et al. The global burden of hip and knee osteoarthritis: Estimates from the Global Burden of Disease 2010 study. *Ann Rheum Dis* 2014;73:1323-1330.
2. Persson F, Turkiewicz A, Bergkvist D, Neuman P, Englund M. The risk of symptomatic knee osteoarthritis after arthroscopic meniscus repair vs partial meniscectomy vs the general population. *Osteoarthritis Cartilage* 2018;26:195-201.
3. Teichtahl AJ, Cicuttini FM, Abram F, et al. Meniscal extrusion and bone marrow lesions are associated with incident and progressive knee osteoarthritis. *Osteoarthritis Cartilage* 2017;25:1076-1083.
4. Foreman SC, Neumann J, Joseph GB, et al. Accelerated knee osteoarthritis is nearly always associated with meniscal breakdown: Data from the osteoarthritis initiative. *Osteoarthritis Cartilage* 2018;26:S443-S444.
5. Moatshe G, Chahla J, Slette E, Engebretsen L, LaPrade RF. Posterior meniscal root injuries. *Acta Orthop* 2016;87:452-458.
6. Smith NA, Parkinson B, Hutchinson CE, Costa ML, Spalding T. Is meniscal allograft transplantation chondroprotective? A systematic review of radiological outcomes. *Knee Surg Sports Traumatol Arthrosc* 2016;24:2923-2935.
7. Rosso F, Bisicchia S, Bonasia DE, Amendola A. Meniscal allograft transplantation: A systematic review. *Am J Sports Med* 2014;43:998-1007.
8. Gomoll AH, Minas T. The quality of healing: Articular cartilage. *Wound Repair Regen* 2014;22:30-38.
9. Feucht MJ, Kuhle J, Bode G, et al. Arthroscopic transtibial pullout repair for posterior medial meniscus root tears: A systematic review of clinical, radiographic, and second-look arthroscopic results. *Arthroscopy* 2015;31:1808-1816.
10. Li Y, Zhang H, Zhang J, Li X, Song G, Feng H. Clinical outcome of simultaneous high tibial osteotomy and anterior cruciate ligament reconstruction for medial compartment osteoarthritis in young patients with anterior cruciate ligament-deficient knees: A systematic review. *Arthroscopy* 2015;31:507-519.
11. Papalia R, Papalia G, Russo F, et al. Meniscal extrusion as booster of osteoarthritis. *J Biol Regul Homeost Agents* 2017;31:33-44 (suppl 2).
12. Myers P, Tudor F. Meniscal allograft transplantation: How should we be doing it? A systematic review. *Arthroscopy* 2015;31:911-925.