

## First autochthone case of sporotrichosis by *Sporothrix globosa* in Portugal<sup>☆</sup>

Manoel Marques Evangelista de Oliveira<sup>a,b,\*</sup>, Cristina Veríssimo<sup>c</sup>, Raquel Sabino<sup>c</sup>, João Aranha<sup>d</sup>, Rosely Maria Zancopé-Oliveira<sup>b</sup>, Paula Sampaio<sup>a</sup>, Célia Pais<sup>a</sup>

<sup>a</sup> Centre of Molecular and Environmental Biology (CBMA), Department of Biology, University of Minho, Braga, Portugal

<sup>b</sup> Laboratório de Micologia, Instituto de Pesquisa Clínica Evandro Chagas, Fundação Oswaldo Cruz, Rio de Janeiro, Brazil

<sup>c</sup> Laboratório de Micologia, Departamento de Doenças Infecciosas, Instituto Nacional de Saúde Dr. Ricardo Jorge (INSA), Lisboa, Portugal

<sup>d</sup> Hospital Distrital de Santarém, Santarém, Portugal

### ARTICLE INFO

#### Article history:

Received 28 May 2013

Received in revised form 8 August 2013

Accepted 11 August 2013

Available online 15 January 2014

#### Keywords:

*Sporothrix globosa*

Sporotrichosis

Portugal

Autochthone case

T3B

### ABSTRACT

In this study, we characterize the first autochthone case of human sporotrichosis reported in Lisbon, Portugal. Phenotypic and genotypic characterization revealed that the infection was caused by *Sporothrix globosa*. We conclude that sporotrichosis may be underdiagnosed particularly in Southern Europe and suggest Portugal as an emerging area for this fungal infection.

© 2014 Elsevier Inc. All rights reserved.

Sporotrichosis is a subcutaneous cosmopolitan mycosis that affects humans and other animals, with Latin America, South Africa, India, and Japan as the areas of high endemicity (Lopez-Romero et al., 2011). This infection is caused by the dimorphic fungus previously described as a single species, *Sporothrix schenckii*, but recently, the so-called *S. schenckii* complex has been described comprising the medically relevant agents of sporotrichosis, *Sporothrix brasiliensis*, *Sporothrix globosa*, *Sporothrix luriei*, *Sporothrix mexicana*, and *Sporothrix schenckii sensu stricto* (Marimon et al., 2007, 2008; de Meyer et al., 2008). Other species such as *Sporothrix pallida* have only been isolated from the environment (Marimon et al., 2007, 2008; de Meyer et al., 2008; Madrid et al., 2009; Romeo et al., 2011). An identification key for the *Sporothrix* species complex differentiation has been proposed (Marimon et al., 2007) including analysis of conidial morphology, auxonogram analysis of raffinose and sucrose assimilation, and sequencing of calmodulin (CAL) and/or  $\beta$ -tubulin ( $\beta$ -tub) genes (Marimon et al., 2007; Oliveira et al., 2011; Rodrigues et al., 2013). Recently, Zhou et al. (2013) suggested that internal transcribed spacer region analysis could also be applied for identification at the species level of the *Sporothrix* complex.

In humans, sporotrichosis is usually associated with puncture injuries in farmers, florists, leisure gardeners, nursery workers, landscapers, or greenhouse workers. In 2008, a sporotrichosis epidemic was described in Rio de Janeiro, Brazil, in which the transmission of

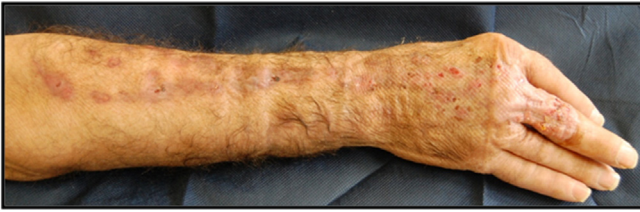
the disease occurred mainly through scratches or bites of *S. schenckii sensu lato*-infected cats (Schubach et al., 2008). Few cases of sporotrichosis have been described in Europe, mainly in Italy but also in Spain, United Kingdom, and Portugal (Cafarchia et al., 2007; Dias et al., 2011). However, the Portuguese case of human sporotrichosis due to *S. mexicana* occurred in a patient who had traveled to Malaysia in 2003 and, therefore, could not be regarded as autochthone (Dias et al., 2011).

In this study, we characterize a new case of human sporotrichosis identified in Lisbon. This case occurred in an immunocompetent patient, which developed skin lesion in the right hand with localized lymphocutaneous sporotrichosis (Fig. 1). The patient did not remember the date or the local where the trauma occurred and, to our knowledge, has never left Portugal. Skin biopsy was received at the INSA Mycology Laboratory for testing. Direct microscopic examination with 10% KOH and culture of biopsy fragments on enriched medium (Blood agar) and Sabouraud agar, followed by incubation at 35 °C for 5–10 days, allowed the isolation of strain INSA378027. The infecting isolate was initially identified as *S. schenckii* based on morphologic features. In order to confirm the identity of the isolate, a detailed phenotypic analysis was performed, including 4 control strains: the type strain of *S. brasiliensis* CBS 120339 (former IPEC16490) (Marimon et al., 2007) and the reference strains IPEC27722 (*S. schenckii*), IPEC27135 (*S. globosa*), and MUM11.02 (*S. mexicana*) (Dias et al., 2011; Oliveira et al., 2010, 2011). The microscopic features and sporulation analyzed in Cornmeal and Potato dextrose agar (PDA) showed clusters of intercalary or terminal conidia formed by sympodial growth from differentiated conidiophores on both media. Sympodial

<sup>☆</sup> Transparency Declaration: All authors declare no conflicting interests.

\* Corresponding author. Tel.: +55-21-3865-9640; fax: +55-21-3865-9557.

E-mail addresses: [manoel.marques@ipecc.fiocruz.br](mailto:manoel.marques@ipecc.fiocruz.br), [manoelmeo@gmail.com](mailto:manoelmeo@gmail.com) (M.M.E. Oliveira).



**Fig. 1.** Skin lesion on the right hand of patient with localized lymphocutaneous sporotrichosis.

conidia were hyaline or slightly pigmented. Sessile conidia were predominantly globose and dematiaceous (Fig. 2C and D). The colony diameter on PDA after 21 days of incubation attained 35 mm at 30 °C (Fig. 2B) and 5 mm at 37 °C (Fig. 2A). The conversion to the yeast form was achieved by incubating the isolate on Brain Heart Infusion agar slants at 35 °C ± 2 °C for 7 days in a single subculture. Carbohydrate assimilation tests run in triplicate showed that the *Sporothrix* isolate (INSA378027) assimilated glucose as well as sucrose and did not assimilate raffinose, an atypical phenotype of *S. globosa* species (Marimon et al., 2007).

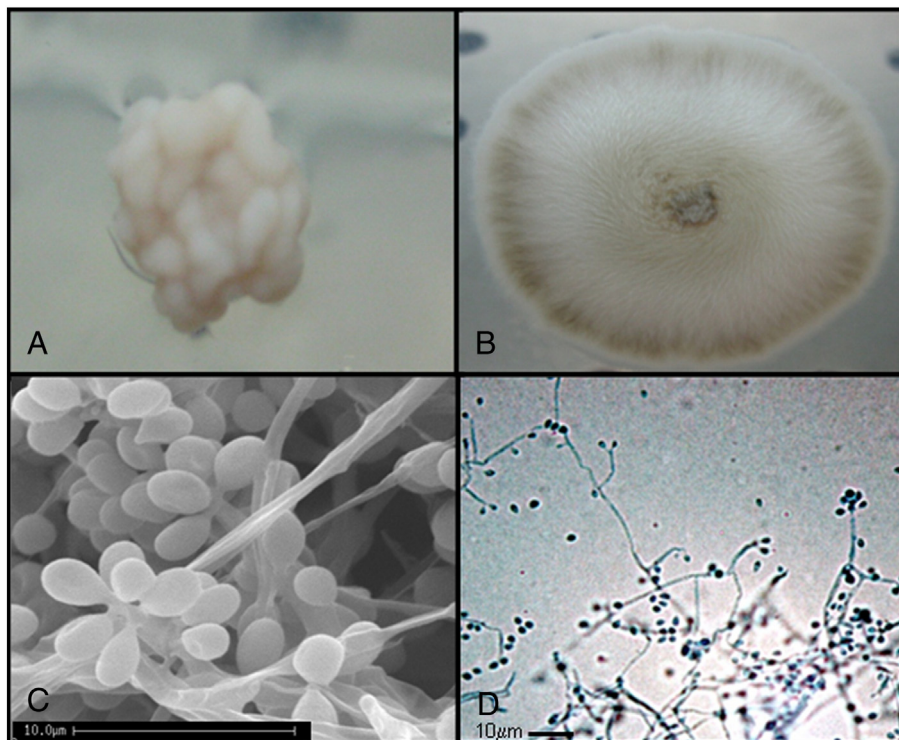
Genomic DNA was extracted from the mycelial phase for sequencing of the partial  $\beta$ -tub-encoding gene (Marimon et al., 2007) and partial CAL-encoding gene (Oliveira et al., 2010) and for T3B PCR fingerprinting (Oliveira et al., 2012). The BLAST analysis comparing the  $\beta$ -tub and CAL sequences obtained for INSA378027 isolate in the NCBI GenBank database identified this isolate as *S. globosa* with 99–100% similarity with other *S. globosa* sequences (AM116961, AM116964, AM116965, AM116966, AM116967, GU456632, KC121567, AM116907, AM116908). Moreover, comparison and phylogenetic analysis of the partial  $\beta$ -tub and CAL sequences obtained from *S. globosa* strain INSA378027 with the reference strain FMR8600 available in GenBank database presented 100% similarity among them and also showed high bootstrap support values for both genes (Fig. 3A and B). The /sequences obtained for  $\beta$ -tub- and CAL-encoding

genes were deposited in the GenBank database under accession number KC716083 and KF437620. The T3B PCR fingerprinting profile obtained for strain INSA378027 was identical to the *S. globosa* reference strain, corroborating once more the *S. globosa* identification (Fig. 3C). *In vitro* antifungal disk diffusion susceptibility testing was determined (CLSI, 2010) and showed an inhibition zone diameter of 50 mm to ketoconazole and 40 mm to miconazole, suggesting *in vitro* susceptibility to these antifungals. However, the disk inhibition zone diameter to fluconazole, itraconazole, and voriconazole was less than 0.5 mm, indicating *in vitro* reduced susceptibility to these antifungals, data similar to those reported by other study with isolates of *S. globosa* (Marimon et al., 2008). Overall, our results indicate that the reported infection was due to *S. globosa* and highlight the need of an integrated phenotypic and molecular analysis for the identification of *Sporothrix* isolates, as previously suggested (Oliveira et al., 2011; Rodrigues et al., 2013; Zhou et al., 2013).

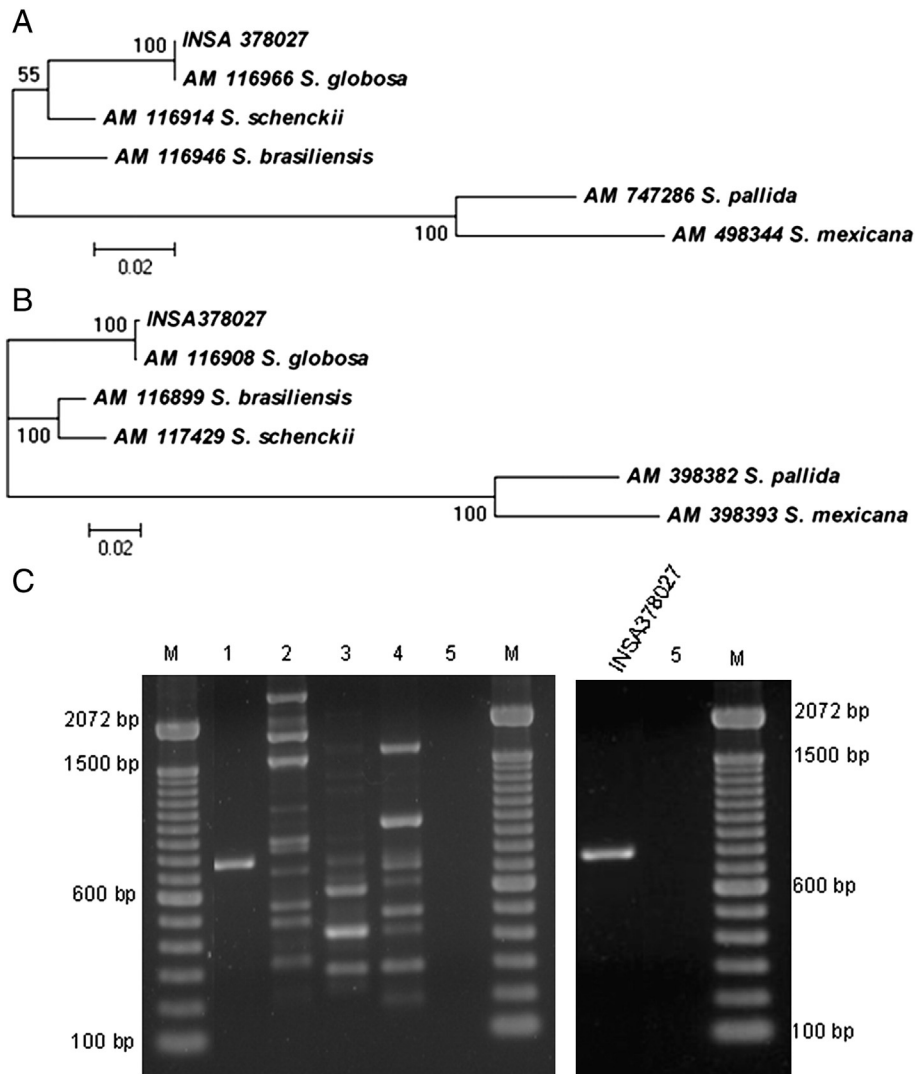
Isolates of *S. globosa* have been reported from United Kingdom, Spain, Italy, China, Japan, USA, India, Mexico, Guatemala, Brazil, and Colombia (Madrid et al., 2009; Cafarchia et al., 2007; Dias et al., 2011; Oliveira et al., 2010, 2011). In this study, we report the identification of the first autochthone sporotrichosis case in Portugal due to *S. globosa* and showing *in vitro* reduced susceptibility to fluconazole, itraconazole, and voriconazole. This report indicates that sporotrichosis may be underdiagnosed particularly in Southern Europe and suggests Portugal as an emerging area for this fungal infection.

#### Acknowledgments

This research was supported by FEDER funds through the Operational Programme COMPETE and national funds through Fundação para a Ciência e Tecnologia, in the scope of project PEst-C/BIA/UI4050/2011, and by FAPERJ/Rio de Janeiro, Brazil (grant proc. E-26/110.619/2012). R. M. Z-O. is supported in part by CNPq 350338/2000-0 and



**Fig. 2.** *S. globosa*: morphological aspects at 37 °C (A), and 30 °C (B). SEM photograph showing the sessile conidia (C), Sessile conidia 400× (D).



**Fig. 3.** Neighbor-joining phylogram of the partial  $\beta$ -tub (A) and partial CAL (B) gene obtained of INSA378027 isolate and *S. mexicana*, *S. albicans*, *S. brasiliensis*, *S. schenckii*, and *S. globosa* reference strains constructed with MEGA version 4.0.2. Bootstrap values after 1000 replicates are presented in the branch node. (C) Comparison of the T3B PCR fingerprinting profiles obtained for INSA378027 isolate with the *Sporothrix* reference strains: (1) *S. globosa* (IPEC 27135), (2) *S. mexicana* (MUM 11.02), (3) *S. brasiliensis* (IPEC 16490), (4) *S. schenckii* (IPEC27722), (5) negative control and (M) Molecular marker DNA ladder, 100 bp (Invitrogen).

FAPERJ E-26/103.157/2011. M. M. E. O. was supported by a grant from CAPES 2445/11-5.

## References

- Cafarchia C, Sasanelli M, Lia RP, de Caprariis D, Guillot J, Otranto D. Lymphocutaneous and nasal sporotrichosis in a dog from southern Italy: case report. *Mycopathologia* 2007;163(2):75–9.
- Clinical and Laboratory Standards Institute (CLSI). Reference method for antifungal disk diffusion susceptibility testing of non dermatophyte filamentous fungi, approved guideline, first edition, 51-A. Wayne, PA: CLSI; 2010.
- de Meyer EM, de Beer ZW, Summerbell RC, Moharram AM, de Hoog GS, Vismar HF, Wingfield MJ. Taxonomy and phylogeny of new wood- and soil-inhabiting *Sporothrix* species in the *Ophiostoma stenoceras-Sporothrix schenckii* complex. *Mycologia* 2008;100(4):647–61.
- Dias NM, Oliveira MM, Santos C, Zancope-Oliveira RM, Lima N. Sporotrichosis caused by *Sporothrix mexicana* Portugal. *Emerg Infect Dis* 2011;17(10):1975–6.
- Lopez-Romero E, Reyes-Montes M del R, Perez-Torres A, Ruiz-Baca E, Villagomez-Castro JC, Mora-Montes HM, Flores-Carreón A, Toriello C. *Sporothrix schenckii* complex and sporotrichosis, an emerging health problem. *Future Microbiol* 2011;6:85–102.
- Madrid H, Cano J, Gene J, Bonifaz A, Toriello C, Guarro J. *Sporothrix globosa*, a pathogenic fungus with widespread geographical distribution. *Rev Iberoam Micol* 2009;26: 218–22.
- Marimon R, Cano J, Gene J, Sutton DA, Kawasaki M, Guarro J. *Sporothrix brasiliensis*, *S. globosa*, and *S. mexicana*, three new *Sporothrix* species of clinical interest. *J Clin Microbiol* 2007;45:3198–206.
- Marimon R, Gene J, Cano J, Guarro J. *Sporothrix luriei*: a rare fungus from clinical origin. *Med Mycol* 2008;46:621–5.
- Oliveira MME, de Almeida-Paes R, de Medeiros Muniz M, de Lima Barros MB, Galhardo MC, Zancope-Oliveira RM. Sporotrichosis caused by *Sporothrix globosa* in Rio de Janeiro, Brazil: case report. *Mycopathologia* 2010;169(5):359–63.
- Oliveira MME, Almeida-Paes R, Muniz MM, Gutierrez-Galhardo MC, Zancope-Oliveira RM. Phenotypic and molecular identification of *Sporothrix* isolates from an epidemic area of sporotrichosis in Brazil. *Mycopathologia* 2011;172(4): 257–67.
- Oliveira MME, Sampaio P, Almeida-Paes R, Pais C, Gutierrez-Galhardo MC, Zancope-Oliveira RM. Rapid identification of *Sporothrix* species by T3B fingerprinting. *J Clin Microbiol* 2012;50:2159–62.
- Rodrigues AM, de Hoog S, de Camargo ZP. Emergence of pathogenicity in the *Sporothrix schenckii* complex. *Med Mycol* 2013;51(4):405–12.
- Romeo O, Scordino F, Criseo G. New insight into molecular phylogeny and epidemiology of *Sporothrix schenckii* species complex based on calmodulin-encoding gene analysis of Italian isolates. *Mycopathologia* 2011;172(3):179–86.
- Schubach A, Barros MB, Wanke B. Epidemic sporotrichosis. *Curr Opin Infect Dis* 2008;21:129–33.
- Zhou X, Rodrigues AM, Feng P, Hoog GS. Global ITS diversity in the *Sporothrix schenckii* complex. *Fungal Diversity* 2013; [epub ahead of print].